

# Increased Expression of the Remodeling- and Tumorigenic-Associated Factor Osteopontin in Pyramidal Neurons of the Alzheimer's Disease Brain

John K. Wung<sup>1</sup>, George Perry<sup>1</sup>, Aaron Kowalski<sup>2</sup>, Peggy L.R. Harris<sup>1</sup>, Glenda M. Bishop<sup>1,5</sup>, Mehul A. Trivedi<sup>3</sup>, Sterling C. Johnson<sup>3</sup>, Mark A. Smith<sup>1</sup>, David T. Denhardt<sup>2</sup> and Craig S. Atwood<sup>1,3,4,\*</sup>

**FINAL**

<sup>1</sup>Institute of Pathology, Case Western Reserve University, 2085 Adelbert Road, Cleveland, Ohio 44106 USA; <sup>2</sup>Nelson Laboratories, Rutgers University, Piscataway, New Jersey 08854, USA; <sup>3</sup>Department of Medicine, University of Wisconsin and Geriatric Research, Education and Clinical Center, Veterans Administration Hospital, 2500 Overlook Terrace, Madison, WI, 53705, USA; <sup>4</sup>School of Exercise, Biomedical and Health Sciences, Edith Cowan University, Jondalup, WA 6027, Australia; <sup>5</sup>Current Address: School of Psychology, Psychiatry and Psychological Medicine, Monash University, Clayton, VIC, 3800, Australia

**Abstract:** Osteopontin (OPN) is a glycoposphoprotein expressed by several cell types and has pro-adhesive, chemotactic, and cytokine-like properties. OPN is involved in a number of physiologic and pathologic events including angiogenesis, apoptosis, inflammation, oxidative stress, remyelination, wound healing, bone remodeling, cell migration and tumorigenesis. Since these functions of OPN, and the events that it regulates, are involved with neurodegeneration, we examined whether OPN was differentially expressed in the hippocampus of the Alzheimer's disease (AD) compared with age-matched (59-93 years) control brain. We report for the first time the immunocytochemical localization of OPN in the cytoplasm of pyramidal neurons. In AD brains, there was a significant 41 % increase in the expression of neuron OPN compared with age-matched control brain. No staining of other neuronal cell types was observed. Additionally, there was a significant positive correlation between OPN staining intensity and both amyloid- load ( $r^2 = 0.25$ ;  $P < 0.05$ ;  $n = 20$ ) and aging ( $r^2 = 0.32$ ;  $P < 0.01$ ;  $n = 20$ ) among all control and AD subjects. Controlling for age indicated that OPN expression was significantly influenced by amyloid- load, but not age. While the functional consequences of this amyloid- associated increase in OPN expression are unclear, it is notable that OPN is primarily localized to those neurons that are known to be vulnerable to AD-related neurite loss, degeneration and death. Given that the induction of OPN expression (and amyloid- generation) is associated with remodeling and tumorigenesis, our results suggest that OPN may play a role in the aberrant re-entry of neurons into the cell cycle and/or neuronal remyelination in AD.

**Keywords:** Osteopontin, tumorigenesis, remodeling, repair, inflammation, amyloid- , neuron, Alzheimer's disease, aging, cell cycle.

## INTRODUCTION

Alzheimer's disease (AD) is invariably associated with and defined by neuron death, synapse loss and the presence of extracellular deposits of amyloid (senile plaques) and intracellular neurofibrillary tangles (NFT's) in the brain and cerebral blood vessels [1]. NFT's are composed primarily of highly phosphorylated tau in paired helical filaments while senile plaques are composed primarily of fibrillar amyloid- [2, 3]. Amyloid- is a 39-42 amino acid protein derived from the amyloid- protein precursor (A $\beta$ ) via proteolytic cleavage at the - and -secretase cleavage sites. Associated with these pathogenic and biochemical changes is a chronic inflammatory response, oxidative stress and altered metal ion metabolism [4]. A central hypothesis that has developed over the last decade that explains the presence of all these bio-

chemical and pathological changes in the AD brain is the aberrant re-entry of differentiated neurons into the cell cycle [reviewed in 5, 6]. Identifying factors that regulate the neuron cell cycle is therefore important for our understanding of disease progression.

Osteopontin (OPN) is a negatively charged, acidic, hydrophilic, glycol-phosphoprotein that is constitutively expressed in several cell types (bone, neurons, fibroblasts, endothelial cells, epithelial cells, macrophages, and smooth muscle cells), and that also is expressed and secreted in numerous human cancers. OPN functions in cell adhesion, chemotaxis, macrophage-directed interleukin-10 (IL-10) suppression, stress-dependent angiogenesis, prevention of apoptosis, and anchorage-independent growth of tumor cells by regulating cell-matrix interactions and cellular signaling through binding with integrin and CD44 receptors [7-11]. Induced expression of OPN has been detected in T-lymphocytes, epidermal cells, bone cells, macrophages, and tumor cells in remodeling processes such as inflammation, ischemia-reperfusion, bone resorption, and tumor progres-

\*Address correspondence to this author at the University of Wisconsin-Madison, School of Medicine and Public Health, Wm S. Middleton Memorial VA (GRECC 11G), 2500 Overlook Terrace, Madison, WI 53705, USA; Tel: 608 256-1901, Ext. 11664; Fax: 608 280-7291; E-mail: csa@medicine.wisc.edu

sion [11]. OPN expression also is increased in transformed cells, including breast cancer, prostate cancer, osteosarcoma, glioblastoma and squamous cell carcinoma [12, 13]. Recently, substantial evidence has linked OPN with the regulation of metastatic spread by tumor cells. This may reflect inducible expression that is secondary to oncogene transformation [14, 15]. Importantly, transfection of cells with OPN increases their malignant phenotype [16-18]. That OPN plays a central role in tumorigenesis is strongly supported by studies showing that *ras* transformation of cells from OPN knockout mice results in impaired colony formation in soft agar and slow tumor growth *in vivo* compared with wild-type mice [19]. OPN appears to contribute to malignancy through both inhibition of apoptosis and activation of various matrix-degrading proteases.

Given the above actions of OPN in remodeling and tumorigenesis, we assessed whether the expression of OPN was altered in AD brains. We find that OPN expression is increased 41 % in AD compared to age-matched control brain, and that OPN expression is positively correlated with both amyloid- and age. OPN expression was dependent upon amyloid- load but not age. These results suggest that OPN may be upregulated as a result of cell cycle-related changes and/or as a compensatory response to neuronal degeneration in the AD brain.

## MATERIALS AND METHODS

### Tissue Sections

Hippocampus tissue from pathologically confirmed AD cases (n = 10; ages 59-93, average = 80.7 years; postmortem interval (PMI) 3-13 h, average = 7.89 h) and age-matched controls (n = 10; ages 67-86, average = 77.0 years; PMI 4-27 h, average = 15.2 h) were fixed in methacarn (methanol:chloroform:acetic acid; 6:3:1) overnight at 4° C. Ages and postmortem interval of AD and age-matched controls were not significantly different. All of the AD cases met the CERAD (Consortium to Establish a Registry for Alzheimer's Disease) criteria for AD. The tissue was then embedded in paraffin and cut into 7 µm sections that were placed on silane-coated slides (Sigma, St. Louis, MO, USA).

### Immunocytochemistry

Paraffin was removed from the tissue sections with xylene and then hydrated through a series of graded ethanol. Endogenous peroxidase activity was eliminated with a 30 min. incubation in 3 % H<sub>2</sub>O<sub>2</sub> in methanol. Following hydration, the sections were rinsed in Tris-buffered saline (TBS; 50 mM Tris-HCl and 150 mM NaCl, pH 7.6) and then treated with 70% formic acid for 5 min. at room temperature. Nonspecific binding sites were blocked by 30 min. incubation with 10 % normal goat serum in TBS prior to primary antibody application. OPN was detected using a mouse monoclonal antibody, Akm2A1 (5µg/mL) [20]. Amyloid- deposition was detected in serial sections using the mouse monoclonal antibody, 4G8 (1:1000; Signet Laboratories, Dalham, MA). The primary antibodies were omitted in serial section controls. Immunostaining was developed by the peroxidase-antiperoxidase procedure [21] using 3,3'-diaminobenzidine (Dako, Glostrup, Denmark) as the cosubstrate.

## Immunohistochemical Staining Quantitation

Three adjacent fields of hippocampus were viewed with a Zeiss Axiophot microscope (20x objective; total area 1 mm<sup>2</sup>) with an attached Zeiss Axiocam digital camera and Zeiss Image Analysis system (KS300). The intensity of the immunoreaction for OPN in each field was determined by measuring the average optical density (OD) of the cytoplasm and nucleus of pyramidal neurons as previously described [22]. The OD for each field was corrected for background by subtracting the OD of an adjacent area that did not contain positive staining. The proportion of amyloid plaques in serial sections also was determined as described above and the relative area of the plaques was calculated and then averaged as previously described [22].

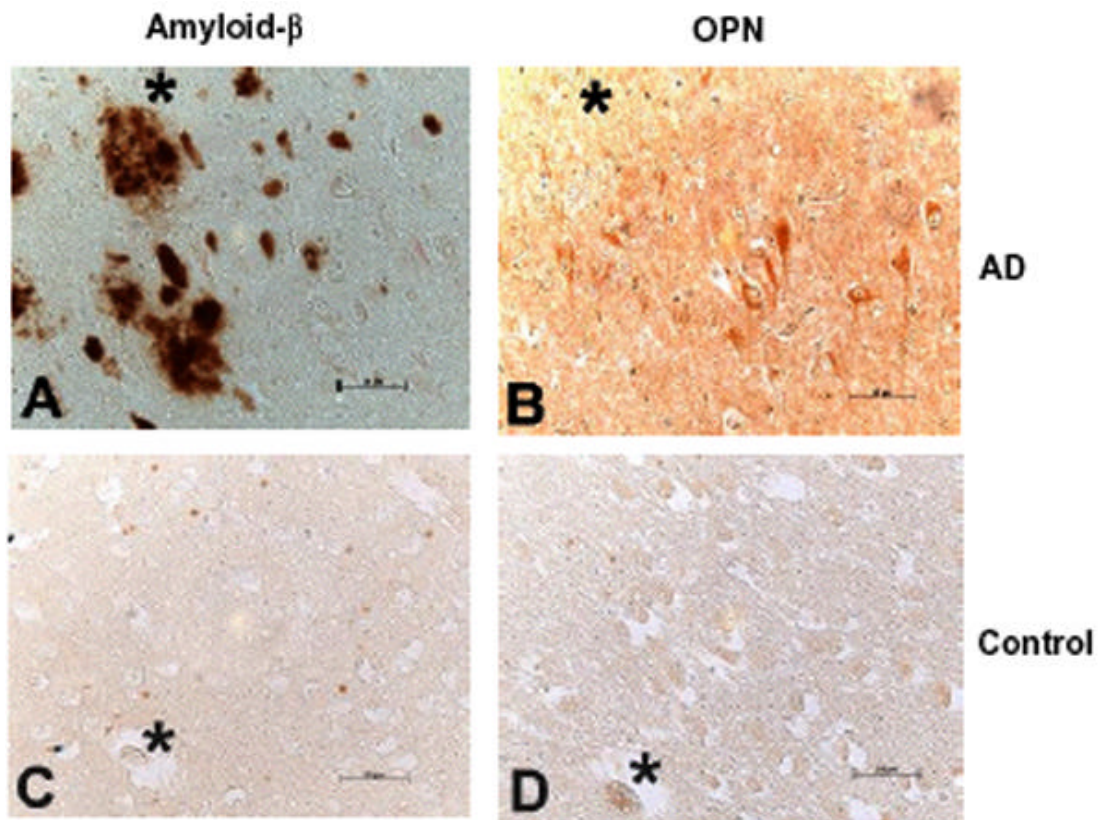
## Statistical Analyses

Students *t*-test (independent, two-tailed, assuming unequal variances; Statview 5.0; SAS Institute, Inc.) was performed on OPN staining intensity and amyloid- load between control and AD brains to determine statistically significant differences. Simple and partial correlational analyses were conducted between neuronal OPN staining, amyloid load, age, PMI and sex using the Statview 5.0 and SPSS (Version 12.0) statistical programs.

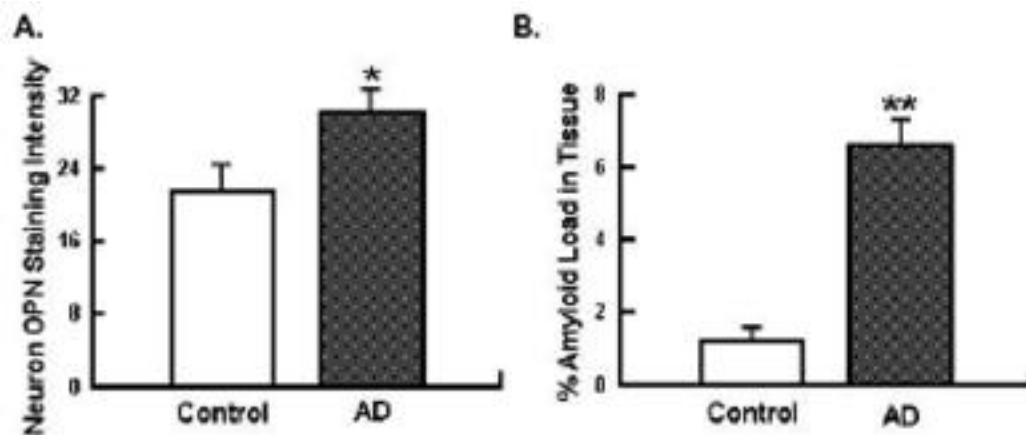
## RESULTS

To examine if OPN was expressed in neurons of the hippocampus, and whether there were changes in the expression of this tumorigenic marker during neurodegeneration, hippocampal tissue from AD and age-matched controls was sectioned and stained using the OPN monoclonal antibody Akm2A1. Immunocytochemical analyses indicated OPN immunoreactivity in the cytoplasm of pyramidal neurons in both AD (Fig. 1B) and age-matched control subjects (Fig. 1D). Quantitative analysis of the CA1 region revealed a significant 41 % increase in the level of OPN in this neuron population in AD compared with age-matched control brains (Fig. 2A; *p* < 0.05; *n* = 10), an increase that remained significant (*p* < 0.05) after correcting for age. Stained neurons were apparent throughout the CA1 region of the hippocampus being distributed along the dentate gyrus and throughout the surrounding tissue. Some elderly control brains with significant neurofibrillary pathology showed intermediate levels of neuronal OPN staining (not shown).

To examine if there was an association between amyloid- deposition and OPN expression, serial sections were immunohistochemically stained for amyloid- using the monoclonal antibody 4G8. Extracellular amyloid- deposition was observed throughout the CA1 region of the hippocampus (Fig. 1A) in AD and occasionally in age-matched control brains (Fig. 1C). Amyloid deposits were typically randomly distributed throughout the tissue, although there was a preferential deposition along the dentate gyrus. Quantitative analysis of the CA1 region revealed a significant 5.4-fold increase in the level of amyloid- in this region of the brain compared with age-matched control brains (Fig. 2B; *p* < 0.05; *n* = 10), an increase that remained significant (*p* < 0.05) after controlling for age. No significant correlations were found between amyloid- load and OPN staining intensity among control individuals alone, or among AD individuals



**Fig. (1).** Immunohistochemical staining for OPN in AD versus age-matched control brains. OPN immunostaining in age-matched AD (B) and control brain hippocampal tissue (D) using the monoclonal antibody Akm2A1. Serial sections were stained for amyloid- $\beta$  deposition in AD (A) and control (C) tissues with the antibody 4G8. An 81-yr-old (A, B) AD case and an 81-yr-old control case (C, D). Scale bar = 50  $\mu$ m.



**Fig. (2).** Quantitative analysis of OPN and amyloid- $\beta$  staining. (A) A significant increase in OPN staining was detected in pyramidal neurons of the CA1 region in AD compared with age-matched control brains (Students *t*-test; \**p* < 0.05; *n* = 10). (B) A significant increase in extracellular amyloid- $\beta$  staining in the CA1 region was detected in AD compared with age-matched control brains (Students *t*-test; \*\**p* < 0.0001; *n* = 10).

alone. However, a statistically significant positive correlation was found between amyloid- $\beta$  load and OPN staining intensity among all control and AD subjects (Fig. 3A;  $r^2 = 0.32$ ; *P* < 0.05, *n* = 20). This correlation remained significant after

controlling for age ( $r^2 = 0.22$ ; *P* < 0.05) and PMI ( $r^2 = 0.25$ , *P* < 0.05), suggesting that amyloid- $\beta$  levels influence OPN expression or vice versa independent of age or PMI.

No significant correlations were found for age and OPN staining among control individuals alone, or among AD individuals alone. However, a significant positive correlation was found for age versus OPN staining intensity among all control and AD subjects (Fig. 3B;  $r^2 = 0.25$ ;  $P < 0.01$ ,  $n = 20$ ). Fitting an exponential equation to the data (not shown on Fig. 3B) resulted in a stronger correlation ( $y = 8.6024e^{0.0152x}$ ;  $r^2 = 0.43$ ;  $n = 20$ ), indicating that OPN expression increases exponentially with age. No significant correlations were found between either OPN staining intensity or amyloid- load and PMI or sex.

Figure 3A

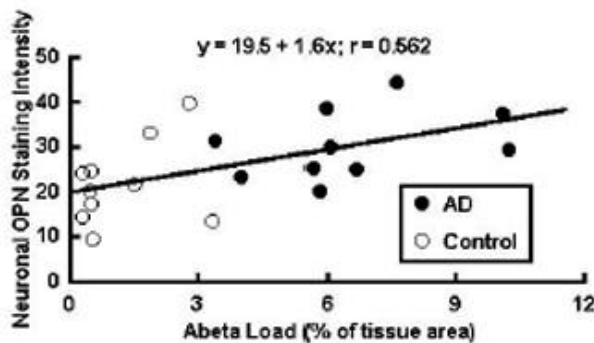
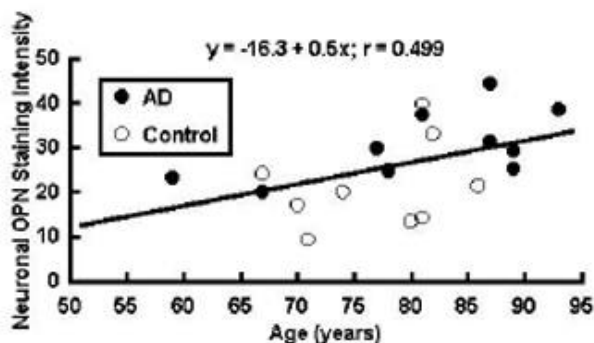


Figure 3B



**Fig. (3).** Regression analysis of neuronal OPN staining with amyloid- load and age. (A) A significant correlation between neuronal OPN staining and extracellular amyloid- load was detected in the CA1 region of control (○) and AD (●) brains ( $r^2 = 0.32$ ;  $P < 0.05$ ,  $n = 20$ ). (B) A significant correlation between neuronal OPN staining and age was detected in the CA1 region of control (○) and AD (●) brains ( $r^2 = 0.25$ ;  $p = 0.01$ ;  $n = 20$ ).

## DISCUSSION

In this study we report for the first time the localization of OPN in the cytoplasm of pyramidal neurons in the human brain. Previous studies in rats indicated that OPN mRNA expression is primarily localized to neurons of the olfactory bulb, cerebellum [23] and to the brainstem of rats, where transcripts are found at higher levels in the pons and the medulla than in the midbrain [24]. More recent studies have shown that OPN mRNA and protein is highly expressed in myelinating Schwann cells (SCs) in uninjured rat nerves and

in myelinating SCs in human sural nerves [25]. Axotomy transiently induced OPN expression in the degenerating distal nerve stump of SCs during the first days after injury [25]. Another recent study in rats indicates that OPN expression also is increased in neurons and activated microglia/astrocytes after cryolesioning [26]. We find similar increases in OPN immunoreactivity in the cytoplasm of pyramidal neurons in the brain of individuals affected by AD in comparison to age-matched controls (Figs. 1B & D). Notably, OPN was concentrated only in those neurons vulnerable to AD-related neurodegeneration (NFT's). Consistent with an earlier report demonstrating increased OPN expression with age in mouse macrophages [27], we also find an increase in OPN expression with age in neurons. The presence of elevated levels of OPN in the cytoplasm of neurons in individuals with AD and with aging may be due to one or more of the following: 1) increased intracellular OPN expression; 2) decreased intracellular OPN degradation; 3) decreased OPN secretion and/or 4) increased OPN sequestration from extracellular sources. Since OPN immunoreactivity in macrophages, neurons, and astrocytes was shown to disappear by day 14 post-injury in cryolesioned rat brains [26] and to reach low levels by day 14 in SCs following axotomy [25], our results suggest that increases in OPN expression in neurons with aging and AD is likely a response to the age-related neurodegeneration of the brain that is accelerated in AD.

Demyelination has been suggested as a contributing factor to the pathology of brain aging and AD [reviewed in 28]. Interestingly, recombinant OPN treatment has been shown to stimulate both myelin basic protein synthesis and myelin sheath formation in mixed cortical cultures from embryonic mouse brain, an *in vitro* primary culture model of myelination [25, 29]. Thus, given the large synaptic and neuritic loss in the aging and AD brains, the increased expression of OPN may act to upregulate myelination and remyelination during neurodegeneration. That OPN contains an Arg-Gly-Asp (RGD) cell adhesion motif-mediating interactions with several integrins supports the pro-adhesive properties of OPN in remyelination and repair of damaged neurons/neurites.

Pyramidal neurons in the AD brain are associated with cell cycle alterations that can lead to the downstream biochemical and pathological changes associated with AD: tau-phosphorylation, amyloid- deposition, inflammation, oxidative stress, and altered metal ion metabolism [reviewed in 6]. Numerous markers of aberrant cell cycle re-entry have been reported in the AD brain [5, 30]. Since the induction of OPN expression is known to be involved in remodeling processes involved with inflammation and tumorigenesis/metastases, and its expression is increased in numerous transformed cells [12, 13], our results suggest that OPN may play a role in remodeling processes in the AD brain associated with the aberrant re-entry of neurons into the cell cycle. Similarly, amyloid- , which deposits following head injury and was associated with OPN expression (Fig. 3), is generated when neurons that are aberrantly driven to divide [31]. Given that amyloid- is neurogenic to neuronal stem cells [32], amyloid- may play a role in tissue repair following injury. Likewise, increases in OPN expression have been shown to inhibit apoptosis, and promote cell proliferation during times of tissue damage and hypoxia, both of which

are characteristic of AD [33]. OPN induces proliferation of both rat CG-4 and the mouse Oli-neu oligodendrocyte precursor like cell lines in a dose-dependent manner [29]. OPN also has been linked to the proliferation of vascular smooth muscle cells and glomerular mesangial cells subjected to hypoxic conditions [34] as well as promoting angiogenesis following stress and promoting neovascularization [7].

OPN acts in the recruitment and retention of macrophages and T cells to inflammatory areas [35]. Dermal injection of purified OPN has shown to induce an inflammatory infiltrate while the presence of neutralizing anti-OPN antibodies dramatically decreases the macrophage recruitment. Therefore, increased OPN expression in the AD brain also may play a role in the phagocytic microgliosis observed in the AD brain.

Other functions for OPN in the aging brain might include a role in inflammation and oxidative stress. Increased neuronal OPN expression in the AD brain is consistent with that observed in other inflammatory diseases such as arthritis [36], and has been postulated to be a response to tissue degeneration [37]. OPN knockout mice display increased renal dysfunction following renal ischemia-reperfusion injury (a model of NO associated damage) compared with normal mice, indicating a protective function for OPN [38]. Interestingly, OPN has been shown to inhibit inducible nitric oxide synthase (iNOS) expression in both primary renal epithelial cells and macrophages [39]. Thus, OPN may function to protect against NO-induced oxidative damage.

In conclusion, the increase in the expression of OPN correlates with age and disease-related neurodegenerative changes. Whether OPN expression is a response to limit the loss of terminally differentiated and irreplaceable neurons [40], promote neuron regeneration/repair/remodeling and/or one that promotes the re-entry of terminally differentiated neurons into the cell cycle remains to be determined.

## ACKNOWLEDGMENT

This work was supported by funds from the National Institute of Health to CSA (RO1 AG19356) and the Alzheimer's Association. Research in the Denhardt laboratory was supported by funds from the NIH and the Charles and Johanna Busch Foundation.

## REFERENCES

- [1] Hardy J and Selkoe DJ. The amyloid hypothesis of Alzheimer's disease: progress and problems on the road to therapeutics. *Science* 297: 353-6 (2002).
- [2] Glenner GG and Wong CW. Alzheimer's disease: initial report of the purification and characterization of a novel cerebrovascular amyloid protein. *Biochem Biophys Res Commun* 120: 885-90 (1984).
- [3] Masters CL, Simms G, Weinman NA, Multhaup G, McDonald BL, and Beyreuther K. Amyloid plaque core protein in Alzheimer disease and Down syndrome. *Proc Natl Acad Sci USA* 82: 4245-9 (1985).
- [4] Atwood CS, Huang X, Moir RD, Smith MA, Tanzi RE, Roher AE, *et al.* Neuroinflammatory Responses in the Alzheimer's Disease Brain Promote the Oxidative Post-translational Modification of Amyloid Deposits. In: *'Alzheimer's Disease: Advances in Etiology, Pathogenesis and Therapeutics'* (Eds: Iqbal K, Sisodia SS, and Winblad B), John Wiley & Sons, Ltd., London, p. 341-361 (2001).
- [5] Raina AK, Zhu X, Rottkamp CA, Monteiro M, Takeda A, and Smith MA. Cyclin' toward dementia: cell cycle abnormalities and abortive oncogenesis in Alzheimer disease. *J Neurosci Res* 61: 128-33 (2000).
- [6] Atwood CS, Meethal SV, Liu T, Wilson AC, Gallego M, Smith MA, *et al.* Dysregulation of the hypothalamic-pituitary-gonadal axis with menopause and andropause promotes neurodegenerative senescence. *J Neuropathol Exp Neurol* 64: 93-103 (2005).
- [7] Weber GF. The metastasis gene osteopontin: a candidate target for cancer therapy. *Biochim Biophys Acta* 1552: 61-85 (2001).
- [8] Denhardt DT, Noda M, O'Regan AW, Pavlin D, and Berman JS. Osteopontin as a means to cope with environmental insults: regulation of inflammation, tissue remodeling, and cell survival. *J Clin Invest* 107: 1055-61 (2001).
- [9] Khan SA, Lopez-Chua CA, Zhang J, Fisher LW, Sorensen ES, and Denhardt DT. Soluble osteopontin inhibits apoptosis of adherent endothelial cells deprived of growth factors. *J Cell Biochem* 85: 728-36 (2002).
- [10] Butler WT, Ridall AL, and McKee MD. Osteopontin. In: *'Principles of Bone Biology, 2nd edition'* (Eds: Bilezikian JP, Raisz LG, and Rodan GA). Academic Press, San Diego, p. 167-182 (2002).
- [11] Wai PY and Kuo PC. The role of Osteopontin in tumor metastasis. *J Surg Res* 121: 228-41 (2004).
- [12] Senger DR, Asch BB, Smith BD, Perruzzi CA, and Dvorak HF. A secreted phosphoprotein marker for neoplastic transformation of both epithelial and fibroblastic cells. *Nature* 302: 714-5 (1983).
- [13] Senger DR and Perruzzi CA. Secreted phosphoprotein markers for neoplastic transformation of human epithelial and fibroblastic cells. *Cancer Res* 45: 5818-23 (1985).
- [14] Chambers AF, Behrend EI, Wilson SM, and Denhardt DT. Induction of expression of osteopontin (OPN; secreted phosphoprotein) in metastatic, ras-transformed NIH 3T3 cells. *Anticancer Res* 12: 43-7 (1992).
- [15] Barraclough R, Chen HJ, Davies BR, Davies MP, Ke Y, Lloyd BH, *et al.* Use of DNA transfer in the induction of metastasis in experimental mammary systems. *Biochem Soc Symp*. 63: 273-94 (1998).
- [16] Denhardt DT and Guo X. Osteopontin: a protein with diverse functions. *FASEB J* 7: 1475-82 (1993).
- [17] Behrend EI, Craig AM, Wilson SM, Denhardt DT, and Chambers AF. Reduced malignancy of ras-transformed NIH 3T3 cells expressing antisense osteopontin RNA. *Cancer Res* 54: 832-7 (1994).
- [18] Gardner HA, Berse B, and Senger DR. Specific reduction in osteopontin synthesis by antisense RNA inhibits the tumorigenicity of transformed Rat1 fibroblasts. *Oncogene* 9: 2321-6 (1994).
- [19] Wu Y, Denhardt DT, and Rittling SR. Osteopontin is required for full expression of the transformed phenotype by the ras oncogene. *Br J Cancer* 83: 156-63 (2000).
- [20] D'Alonzo RC, Kowalski AJ, Denhardt DT, Nickols GA, and Partridge NC. Regulation of collagenase-3 and osteocalcin gene expression by collagen and osteopontin in differentiating MC3T3-E1 cells. *J Biol Chem* 277: 24788-98 (2002).
- [21] Sternberger LA and Sternberger NH. The unlabeled antibody method: comparison of peroxidase-antiperoxidase with avidin-biotin complex by a new method of quantification. *J Histochem Cytochem* 34: 599-605 (1986).
- [22] Nunomura A, Perry G, Aliev G, Hirai K, Takeda A, Balraj EK, *et al.* Oxidative damage is the earliest event in Alzheimer disease. *J Neuropathol Exp Neurol* 60: 759-67 (2001).
- [23] Lee MY, Choi JS, Lim SW, Cha JH, Chun MH and Chung JW. Expression of osteopontin mRNA in developing rat brainstem and cerebellum. *Cell Tissue Res* 6: 179-85 (2001).
- [24] Shin SL, Cha JH, Chun MH, Chung JW and Lee MY. Expression of osteopontin mRNA in the adult rat brain. *Neurosci Lett* 273: 73-6 (1999).
- [25] Jander S, Bussini S, Neuen-Jacob E, Bosse F, Menge T, Muller HW, *et al.* Osteopontin: a novel axon-regulated Schwann cell gene. *J Neurosci Res* 67: 156-66 (2002).
- [26] Shin T, Ahn M, Kim H, Moon C, Kang TY, Lee JM, *et al.* Temporal expression of osteopontin and CD44 in rat brains with experimental cryolesions. *Brain Res* 1041: 95-101 (2005).
- [27] Rollo EE and Denhardt DT. Differential effects of osteopontin on the cytotoxic activity of macrophages from young and old mice. *Immunology* 88: 642-7 (1996).
- [28] Bartzokis G. Age-related myelin breakdown: a developmental model of cognitive decline and Alzheimer's disease. *Neurobiol Aging* 25: 5-18 (2004).
- [29] Selvaraju R, Bernasconi L, Losberger C, Graber P, Kadi L, Avelana-Adalid V, *et al.* Osteopontin is upregulated during *in vivo* de-

- myelination and remyelination and enhances myelin formation *in vitro*. *Mol Cell Neurosci*. 25: 707-21 (2004).
- [30] Herrup K, Neve R, Ackerman SL, and Copani A. Divide and die: cell cycle events as triggers of nerve cell death. *J Neurosci* 24: 9232-9 (2004).
- [31] McPhie DL, Coopersmith R, Hines-Peralta A, Chen Y, Ivins KJ, Manly SP, *et al.* DNA synthesis and neuronal apoptosis caused by familial Alzheimer disease mutants of the amyloid precursor protein are mediated by the p21 activated kinase PAK3. *J Neurosci*. 23: 6914-6927 (2003).
- [32] Lopez-Toledano MA and Shelanski ML. Neurogenic effect of beta-amyloid peptide in the development of neural stem cells. *J Neurosci*. 24: 5439-5444 (2004).
- [33] Liaw L, Birk DE, Ballas CB, Whitsitt JS, Davidson JM, and Hogan BL. Altered wound healing in mice lacking a functional osteopontin gene (spp1). *J Clin Invest* 101: 1468-78 (1998).
- [34] Sodhi CP, Phadke SA, Batlle D, and Sahai A. Hypoxia stimulates osteopontin expression and proliferation of cultured vascular smooth muscle cells: potentiation by high glucose. *Diabetes* 50: 1482-90 (2001).
- [35] Mazzali M, Kipari T, Ophascharoensuk V, Wesson JA, Johnson R, and Hughes J. Osteopontin--a molecule for all seasons. *QJM* 95: 3-13 (2002).
- [36] Ohshima S, Yamaguchi N, Nishioka K, Mima T, Ishii T, Umeshita-Sasai M, *et al.* Enhanced local production of osteopontin in rheumatoid joints. *J Rheumatol* 10: 2061-7 (2002).
- [37] Attur MG, Dave MN, Stuchin S, Kowalski AJ, Steiner G, Abramson SB, *et al.* Osteopontin: an intrinsic inhibitor of inflammation in cartilage. *Arthritis Rheum* 44: 578-84 (2001).
- [38] Hwang SM, Wilson PD, Laskin JD, and Denhardt DT. Age and development-related changes in osteopontin and nitric oxide synthase mRNA levels in human kidney proximal tubule epithelial cells: contrasting responses to hypoxia and reoxygenation. *J Cell Physiol* 160: 61-8 (1994).
- [39] Rollo EE, Laskin DL, and Denhardt DT. Osteopontin inhibits nitric oxide production and cytotoxicity by activated RAW264.7 macrophages. *J Leukoc Biol* 60: 397-404 (1996).
- [40] Weber GF, Adler B, and Ashkar S. Osteopontin in oxidative stress responses. In: *Inflammatory Cells and Mediators in CNS Diseases* (Eds: Ruffolo RR, Feuerstein GZ, Hunter AJ, Poste G, and Metcalf BW), Harwood Academic, Amsterdam, p. 97-11 (1999).

Received: ?????????????

Revised: ?????????????

Accepted: ?????????????